

# Ablative Fractional Laser Resurfacing for the Treatment of a Third-degree Burn

Jill Waibel MD<sup>a</sup> and Kenneth Beer MD<sup>b</sup>

a. Palm Beach Aesthetic Dermatology and Laser Center, West Palm Beach, FL

b. Jupiter, FL

## ABSTRACT

Burn scars are the result of wound healing following a partial-thickness or full-thickness thermal injury. Thermal injury can frequently result in extensive scarring, which may have profound psychologic impact on the victim, serving as a visible and palpable reminder of a traumatic event. Standard treatments for scars include the use of skin grafts, intralesional steroid injections, and pulsed-dye laser treatments. The authors have previously described successful treatment of a burn scar with nonablative fractional resurfacing.<sup>1</sup> Ablative fractional lasers may offer burn patients advantages over nonablative techniques, including improved function and cosmetic outcomes. In addition, ablative fractional laser may require fewer treatments, and therefore, be a more cost-effective treatment option for patients.

The authors report the use of fractional ablative laser for the treatment of a disfiguring scar that was more than 50 years old. To our knowledge, this is the first report of this technology for the treatment of a scar resulting from a third-degree burn in the literature. The demonstrated successful outcome in this case patient may indicate a progressive treatment option for many patients who have been disfigured by these types of thermal injuries.

## INTRODUCTION

Standard treatments for burn scars include excision, ultrasound, compression therapy, tissue expanders, silicone gel sheeting, intralesional steroids, interferon injections, and laser treatments.<sup>2</sup> Nonfractionated lasers such as argon and traditional CO<sub>2</sub> lasers have been used to treat burn scars but were found to be minimally effective and, in some instances, resulted in additional scarring.<sup>3</sup> Fractional photothermolysis, first introduced by Drs. Manstein and Anderson in 2004,<sup>4</sup> is a means of preserving normal "pixels" of skin during a laser treatment. The authors have previously reported of the successful treatment of a burn scar with a second-generation, erbium-doped, 1550-nm nonablative fractional laser.<sup>2</sup>

Third-degree burns are characterized by the damage to both the epidermis and deep dermis, extending to the level of the subcutaneous tissue, tendon, or bone.<sup>5</sup> These burns result in scarring with a uniquely altered texture, color, pliability, and elasticity, which tends to worsen rather than improve with time. As third-degree burns extend deeper in the dermis than either first-degree or second-degree burns, treatment must also extend to a deeper level. Traditional ablative resurfacing vaporizes an entire plane of tissue at a superficial depth.<sup>6</sup> Fractional ablative lasers have the ability to remove tissue and simultaneously penetrate to the deeper levels that characterize third-degree burns. Ablative fractional laser treatments result in the fractional delivery of focused energy with the ability to abate epidermal and deep dermal tissue with resultant collagen remodeling. Possible ad-

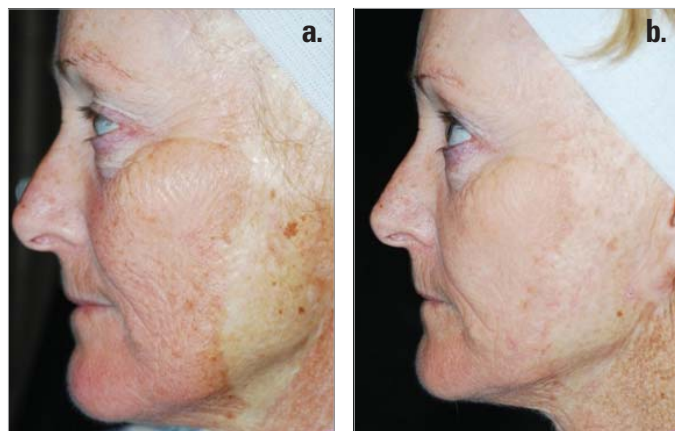
vantages of ablative fractional resurfacing for the treatment of burn scars may be due to several unique aspects of these devices, including stimulating heat shock proteins that promote wound healing. In addition, the depth of penetration of the ablative device may promote healing at a level not treated by the nonablative devices.<sup>7</sup> The unique nature of wound healing following treatment with fractional laser treatments incorporates migration of epithelial cells from adjacent viable tissue and this may be responsible for the unique improvement noted in burn patients. Because of its ability to penetrate deeper into the dermis, the authors postulated that fractional ablative lasers may help to optimize outcomes for the treatment of scars resulting from third-degree burns.

This report discusses the use of ablative fractional resurfacing in a patient with third-degree burn scars. Based on earlier work with burn scars with both nonablative and ablative fractional devices, the authors believe that fractional resurfacing could likely prove as the treatment of choice for burn scars. A brief review of the mechanism of action for fractional laser resurfacing is presented and the implications for the treatment of burn scars are discussed.

## CASE REPORT

A 51-year-old woman presented to our clinic for treatment of scars resulting from a third-degree burn in infancy. The burn had occurred as the result of a home cooking fire that affected her left face, neck, and body. Extensive reconstructive surgeries

**FIGURE 1. a)** Pretreatment: extensive scarring secondary to third-degree burn. **b)** Posttreatment with fractional ablative laser treatment: a noticeable improvement in the texture and appearance of the scar.



were performed utilizing full-thickness grafts to cover some of the areas burned. Parts of the burn were left to heal by secondary intention. In the years following the injury, the scars were treated with revision surgery and intralesional injections of cortisone. The patient reported no adverse events associated with any of these revision treatments; however, significant scarring persisted and this was a significant aesthetic issue for the patient. With the exception of the burn, the past medical history was otherwise unremarkable.

Physical examination revealed a diffuse scarring of the left side of her face and neck (Figure 1). Additionally, the patient (Fitzpatrick skin type 2) was raised in Florida and had significant photodamage as a result of extensive sun exposure when she was younger. The burn scars extended from the middle of her left face to her neck and chest. Marked changes in the texture and tone of her skin were noted with the atrophic scarring, induration, and hypopigmentation being the most prominent. The patient reported being self-conscious of the scars and stated that they had an impact on her self-esteem throughout her life.

Treatment options included pulsed-dye laser, fractional nonablative resurfacing, fractional ablative laser resurfacing, intralesional steroid injection, and surgical grafting following scar excision. Steroid injections may have helped to minimize the

textural changes but had significant potential to cause considerable additional atrophy. Surgical revision with grafts was not deemed appropriate given the extent and duration of the scars. After discussing the risks and benefits of each approach, it was decided to undergo treatment with fractional ablative resurfacing due to textural changes observed in the scar.

A single treatment session using an ablative fractional CO<sub>2</sub> laser (Lumenis; Santa Clara, Calif.) was performed. Two passes were performed using the following parameters: 12.5 mJ/cm<sup>2</sup>, with a density setting of 3 on the first pass with the Deep FX mode and 80 mJ/cm<sup>2</sup>, density setting of 1 on the second pass with the Active FX mode (Table 1).

Preoperatively, the patient had been treated with cephalexin 500 mg twice per day and valacyclovir 500 mg twice per day. In addition, she was treated with acetaminophen with codeine 1 hour prior to the procedure and topical betacaine, lidocaine, and tetracaine compounded topical anesthesia was applied to minimize pain. The postoperative course was uneventful with the exception of nausea that was thought to be a result of pain medications.

## DISCUSSION

It is interesting to consider why the effects of fractional resurfacing treatment of burn scars differs from nonfractional modalities. One obvious parameter is the depth of the injury, which a significantly deeper penetration level can be achieved with fractional modalities to reach deeper aspects of scarring resulting from a higher degree of thermal injury. Collagen remodeling may be significantly more pronounced with the deeper treatments; however, there are many other potential mechanisms of action that need to be considered. Among them is whether or not the ablative fractional lasers promote different heat shock proteins or cytokines based on the type of wound created. It is possible that these cytokines and proteins healing cascades are the cause of the improvement rather than a physical heating of the scar tissue. Another possibility to consider is whether or not different parts of the body are amenable to fractional resurfacing to different degrees. The area of the body treated is likely to be an important determinant of outcome since outcomes with traditional ablative lasers are markedly different when areas such as the neck, chest, and face are treated.<sup>8</sup>

**TABLE 1.**

Ablative fractional CO <sub>2</sub> laser mode specifications						
Laser specifications	Mode	Beam spot size	Scanner area	Density	Energy	Depth
<ul style="list-style-type: none"> <li>• Wavelength: 10600 nm CO<sub>2</sub></li> <li>• Emission/Pulse delivery: Ultrapulse</li> <li>• Pulse duration: 0.01-5 ms</li> <li>• Delivery: Scanning, stamping</li> </ul>	<b>Active FX</b>	1300 microns	9X9 mm	55-100%	80-100 mJ	80-100 microns
	<b>Deep FX</b>	120 microns	7X7 mm	5-25%	5-50 mJ	any

### Patient Factors

When comparing fractional ablative and nonablative modalities for the treatment of scars, one needs to evaluate various patient factors (degree of thermal damage, body area treated, treatment recovery time, and financial limitations) to help determine whether patient is better suited for a single treatment session or multiple sessions. It is likely that treatment of facial scars will tolerate ablative lasers better than nonfacial areas and it is reasonable to initiate CO<sub>2</sub> fractional treatments to the face for burn scar patients. In addition more exploration needs to be done if certain subtypes of scars (atrophic, hypertrophic, keloidal) will respond better to fractional nonablative or fractional ablative resurfacing. Nonablative lasers have less risk of posttreatment erythema, hyperpigmentation, and scarring and these may be appropriate devices with which to initiate treatment for many burn scars. If the scar is recalcitrant to nonablative technology, one can proceed to the ablative modality. Finally, patient counseling is essential for any treatment of existing scars as the potential for worsening them always exists. Patients need to be able to understand and agree to the risks that may include worsening scars, hyperpigmentation, hypopigmentation, and bacterial, viral and fungal infections. For those patients with unrealistic expectations or those that believe that the laser is a "magic wand," this treatment may not be appropriate.

### Safety and Efficacy

Fractional ablative lasers are a relatively new technology and their use for third-degree burn scars has yet to be described. This report documents the safety and efficacy of 1 type of fractional ablative laser for the treatment for a single third-degree burn.

The safety and efficacy of lasers used for treatment of scars has been previously described with the argon, CO<sub>2</sub>, pulsed-dye laser, and nonablative fractional lasers.<sup>9</sup> While the results suggest that this modality holds a great deal of potential for treating this type of scar, many questions remain. For instance, early reports on the treatment of scars located on the extremities with fractional ablative lasers has resulted in prolonged erythema.<sup>10</sup> Experience with traditional CO<sub>2</sub> lasers suggests that treatments for nonfacial areas such as the arms may be associated with higher complication rates.<sup>9</sup> In addition, keloidal, hypertrophic scarring may respond better to nonablative fractional resurfacing whereas atrophic and textural changes may be better treated with ablative fractional resurfacing. The optimal use of either nonablative or ablative fractional resurfacing lasers is at least somewhat dependent on the condition and location of scarring.

### Mechanisms of Action

The role of heat shock proteins (HSP) in wound healing has been described by Laplante et al.<sup>11</sup> These proteins are a family of highly conserved proteins that mediate cellular response to thermal injury and other stressors. Heat shock proteins function primarily as molecular catalysts, facilitating the folding of other cellular

proteins, preventing protein aggregation, or targeting improperly folded proteins to specific degradative pathways. Increased expression of HSPs in a mouse model of epidermis was related to proliferation, migration and differentiation of keratinocytes within wounds.<sup>11</sup>

Fractional photothermolysis thermal damage results in increased expression of heat shock proteins.<sup>9</sup> These, in turn, activate transient amplifying epidermal stem cells located in the basal layer which begin to proliferate to rapidly replace the damaged epidermal tissue. In contrast to nonablative molecular healing, Orringer et al have reported that the ablative CO<sub>2</sub> laser changes collagen via interleukin (IL)-1, tumor necrosis factor (TNF), transforming growth factor (TGF), and matrix metalloproteinases (MMPs).<sup>12</sup> There is clearance of damaged collagen by MMPs then new healthy, collagen is formed. The molecular effects of the fractional ablative devices are currently being studied and once these pathways are better understood may result in more efficacious clinical responses. The response of the epidermal stem cells to heat shock activation may be one reason that fractional laser resurfacing may prove a better method of treating scars, especially those resulting from burns. If the level of HSPs correlates with clinical improvement, methods to optimize HSP production should be defined.

Improvement of the scar treated in the case patient may be due to deeper remodeling that is characteristic of fractional ablative lasers. This is essential to remodeling the deeper aspects of a thick scar. Production of new collagen deep within the dermis may result in a dermal matrix that is more akin to noncicatricial dermis. One study that correlated the depth of dermal injury and resultant scarring was described by Dunkin et al.<sup>13</sup> In this study, the depth of injury that could be sustained without a scar was 0.56 +/- 0.03 mm. Injuries deeper than this resulted in scars. From this observation, it seems intuitively likely that correction of deep scars will require treatment depths of the same depth or deeper. Ablative fractional resurfacing, with a depth of penetration of between 1500 to 2000 microns, has the ability to treat at these depths.

### Method of Treatment

Fractional ablative CO<sub>2</sub> lasers ablate up to 50% of skin's surface with small thermal cores. The untreated fractions of skin remain intact. Stem cells and other epidermal cells enable rapid healing, decreasing recovery time by 80% to 90%.<sup>12</sup> Patients may experience erythema and peeling following the procedure. Average recovery times following the procedures are approximately 5 to 7 days. Complications seen with traditional ablative resurfacing such as infections and persistent erythema are less with the fractional ablative devices.

The optimal number of treatments and depth of ablation required for ideal outcomes remains to be defined but it is likely

that the number of treatments required with the ablative fractional laser will be fewer than with the nonablative devices. Whereas the treatment of rhytids requires treatments of only 100 to 200 microns,<sup>14</sup> these depths will not suffice for scars. In addition, the depth required to treat different types of scars will not be homogenous and thicker scars will likely require deeper procedures. It is important to consider the different lasers abilities to penetrate when selecting devices to treat scars. In addition, it may be possible to determine individual treatments to individual scars by measuring the depth of a given scar with a noninvasive modality such as high frequency ultrasound.

## CONCLUSION

Fractional resurfacing is emerging as a new treatment for scars. Whether or not either nonablative or ablative fractional resurfacing is superior remains to be determined. Clinical trials comparing nonablative fractional resurfacing to ablative fractional resurfacing for the treatment of burn scars will help to define the effectiveness of these modalities. These studies would be worthwhile given the prevalence of the varying burn scars and their economic and psychological burdens on patients. Patients who would benefit from improved treatments, including those who suffer burns from automobile accidents, home fires, and soldiers injured by incendiary devices.

The results of this case suggest that ablative fractional resurfacing is an effective and safe procedure for third-degree burn scars. Additional studies are necessary to assess the validity of these initial observations as well as to determine optimal parameters for treatment. In addition, positive clinical results may stimulate a new area of study that elaborates the molecular mechanisms that underlie this improvement thus provide some pathways for optimizing treatment for various types of scarring.

## DISCLOSURE

Drs. Beer and Waibel are consultants for and have received equipment from Lumenis Ltd.

## REFERENCES

1. Waibel JS, Beer KR. Fractional laser resurfacing for thermal burns. *J Drugs Dermatol*. 2008;7(1):12-14.
2. Xie Y, Zhu KQ, Deubner H, et al. The microvasculature in cutaneous wound healing in the female red Duroc pig is similar to that in human hypertrophic scars and different from that in the female Yorkshire pig. *J Burn Care Res*. 2007;28(3):500-506.
3. Mustoe TA, Cooter RD, Gold MH, et al. International clinical recommendations on scar management. *Plast Reconstr Surg*. 2008;110(2):560-571.
4. Manstein D, Herron GS, Sink RK, et al. Fractional photothermolysis: a new concept for cutaneous remodeling using microscopic patterns of thermal injury. *Lasers Surg Med*. 2004;34(5):426-438.
5. Tredget EE, Nedelec B, Scott PG, Ghahary A. Hypertrophic scars, keloids, and contractures. The cellular and molecular basis for therapy. *Surg Clin North Am*. 1997;77(3):701-730.
6. Alster TS, Nanni CA, Williams CM. Comparison of four carbon dioxide resurfacing lasers. A clinical and histopathologic evaluation. *Dermatol Surg*. 1999;25(9):153-159.
7. Hantash BM, Bedi VP, Kapadia B, et al. In vivo histological evaluation of a novel ablative fractional resurfacing device. *Lasers Surg Med*. 2007;39(2):96-107.
8. Lupton JR, Alster TS. Laser scar revision. *Dermatol Clin*. 2002;20(1):55-65.
9. Tanzi EL, Alster TS. Laser treatment of scars. *Skin Therapy Lett*. 2004;9(1):4-7.
10. Hale E, Sukal S, Bernstein L, et al. Ablative fractional resurfacing for the treatment of moderate to severe acne scarring. Abstract presented at ASLMS Annual Conference. April 4, 2008. Kissimmee, FL
11. Laplante, AF et al. Expression of heat shock proteins in mouse skin during wound healing *J Histochem Cytochem*. 1998;46:1291-1302.
12. Orringer JS, Voorhees JJ, Hamilton T, et al. Dermal matrix remodeling after nonablative laser therapy. *J Am Acad Dermatol*. 2005;54:416-419.
13. Dunkin C, Pleat J, Gillespie P, et al. Scarring occurs at a critical depth of skin injury: precise measurement in a graduated dermal scratch in human volunteers. *Plast Reconstr Surg*. 2007;119(6):1722-1732.
14. Orringer JS, Kang S, Johnson TM, et al. Connective tissue remodeling induced by carbon dioxide laser resurfacing of photodamaged human skin. *Archives*. 2004;140:1322-1332.

## ADDRESS FOR CORRESPONDENCE

### Kenneth Beer MD

1500 North Dixie Highway, Suite 303

West Palm Beach, FL 33401

e-mail ..... kenbeer@aol.com